

A case of imported COVID-19 diagnosed by PCR-positive lower respiratory specimen but with PCR-negative throat swabs

Ryota Hase, Takashi Kurita, Emiri Muranaka, Hiroki Sasazawa, Haruki Mito & Yudai Yano

To cite this article: Ryota Hase, Takashi Kurita, Emiri Muranaka, Hiroki Sasazawa, Haruki Mito & Yudai Yano (2020): A case of imported COVID-19 diagnosed by PCR-positive lower respiratory specimen but with PCR-negative throat swabs, *Infectious Diseases*, DOI: [10.1080/23744235.2020.1744711](https://doi.org/10.1080/23744235.2020.1744711)

To link to this article: <https://doi.org/10.1080/23744235.2020.1744711>



Published online: 02 Apr 2020.



Submit your article to this journal [↗](#)



Article views: 8



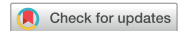View related articles [↗](#)



View Crossmark data [↗](#)



CASE REPORT



A case of imported COVID-19 diagnosed by PCR-positive lower respiratory specimen but with PCR-negative throat swabs

Ryota Hase^{a,b}, Takashi Kurita^a, Emiri Muranaka^{a,b}, Hiroki Sasazawa^{a,b}, Haruki Mito^a and Yudai Yano^a

^aDepartment of Infectious Diseases, Japanese Red Cross Narita Hospital, Narita, Chiba, Japan; ^bDepartment of Infectious Diseases, Kameda Medical Center, Kamogawa, Chiba, Japan

ABSTRACT

A 35-year-old woman presented with fever and mild diarrhoea without any respiratory symptoms 9 days after travelling to Japan from Wuhan, China. Her computed tomography scan revealed pneumonia. The first polymerase chain reaction (PCR) test on throat swab for the novel corona virus upon admission was negative. Therefore, she was treated for community-acquired pneumonia, but fever persisted. On hospital day 5, PCR test on induced sputum was positive, but a second polymerase chain reaction test on throat swab remained negative. She was discharged, fully recovered, on hospital day 12. A lower respiratory tract specimen should be obtained for better diagnosis of corona virus disease 2019, even in the absence of respiratory symptoms for patients with significant travel or exposure history.

KEYWORDS

Coronavirus disease 2019 (COVID-19)
the novel corona virus (SARS-CoV-2)
real-time reverse transcription-polymerase chain reaction (RT-PCR) assay

ARTICLE HISTORY

Received 27 February 2020
Revised 13 March 2020
Accepted 14 March 2020

CONTACT

Ryota Hase
 ryota510@hotmail.com
 90-1 Iidacho, Narita, Chiba, Japan

Introduction

An outbreak of Coronavirus disease 2019 (COVID-19) occurred in Wuhan, China, in December 2019. As of February 25, 2020, 81,109 cases were reported, including 2918 cases in 37 countries other than China [1]. Early and correct diagnosis is crucial to prevent spread of the infection. Polymerase chain reaction (PCR) is used to confirm the microbiological diagnosis. However, sensitivity in different types of specimens remains unclear. The US Centres for Disease Control and Prevention (CDC) recommends that sputum be collected if possible in addition to upper respiratory specimens, but does not regard sputum collection as mandatory [2]. We report a case of a 35-year-old febrile woman without any respiratory symptoms who travelled from Wuhan, China, and were later diagnosed with COVID-19 by real-time reverse-transcription–polymerase chain reaction (RT–PCR) assay on a lower respiratory specimen but was negative on throat swabs.

Case report

The patient was a 35-year-old woman without a significant medical history. On January 21, 2020, she travelled to Japan from Wuhan, China. She was healthy until January 30 when she developed fever with mild diarrhoea. On January 31, at the primary care clinic, the rapid influenza antigen test was negative. Chest X-ray revealed signs of pneumonia in the left lower lung and she was transferred to the Japanese Red Cross Narita Hospital. She denied having sore throat, rhinorrhea, chills and cough. She had not visited Huanan market and was not exposed to any wild or dead animals. On admission, her vital signs were as follows: blood pressure 106/66 mmHg, heart rate 93 beats/min, body temperature 37.9°C, respiratory rate 16 breaths/min and oxygen saturation on room air 97%. Her physical examination was unremarkable. Laboratory test results did not reveal leukocytosis, leukocytopenia or elevated liver function enzymes. Computed tomography (CT) scan showed slight ground-glass opacity in the left lower lung lobe (Figure 1). She was admitted to an isolation room with negative pressure. Ceftriaxone and azithromycin were administered after obtaining a throat swab. The PCR test on the throat swab for the novel coronavirus (SARS-CoV-2) was negative. Her fever persisted but she had no respiratory symptoms such as cough. On hospital day 5, induced sputum and a second throat swab were obtained. The PCR test on induced sputum was positive but the throat swab was still negative. Her

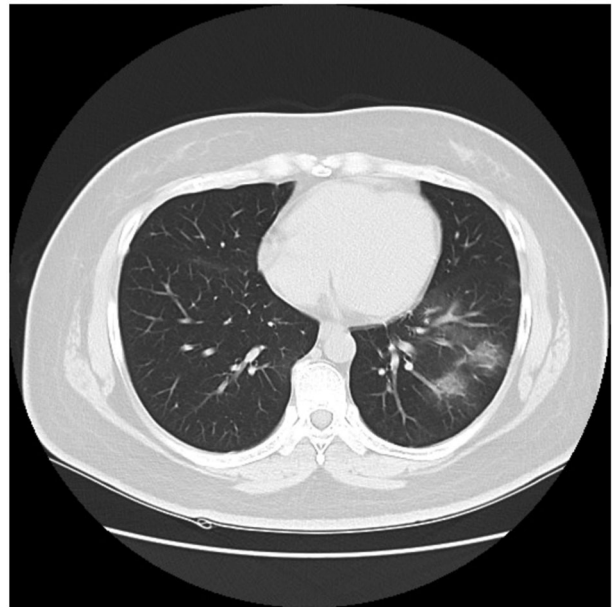

Figure 1. Computed tomography scan showing slight ground-glass opacity in the left lower lobe of the lung.

condition was stable and fever and diarrhoea improved on hospital day 6. She recovered fully and was discharged on hospital day 12 after sputum and throat swab samples tested negative by PCR. During her clinical course, she never had a PCR-positive throat swab (Figure 2). All PCR tests were performed at the reference laboratory by real-time RT-PCR assays following a previously described method [3].

Discussion

This case of imported COVID-19 highlights some important clinical issues. First, a lower respiratory tract specimen should be obtained for diagnosis of COVID-19 when clinically suspected even if throat swabs are negative. Second, COVID-19 cannot be ruled out by the absence of respiratory symptom in patients with significant travel or exposure history.

Our case suggests that negative PCR test on throat swabs may not be enough to rule out COVID-19. Therefore, lower respiratory tract specimens should be obtained for diagnosis when clinical suspicion is high. Although the evidence on COVID-19 remains unclear, in patients with severe acute respiratory syndrome (SARS) and Middle East respiratory syndrome (MERS) lower respiratory tract specimens contain the highest viral loads [4,5]. The CDC guideline suggests that lower respiratory specimens are the preferred clinical specimens for diagnosis of MERS [6]. Another study also suggested that upper respiratory specimens are not suitable

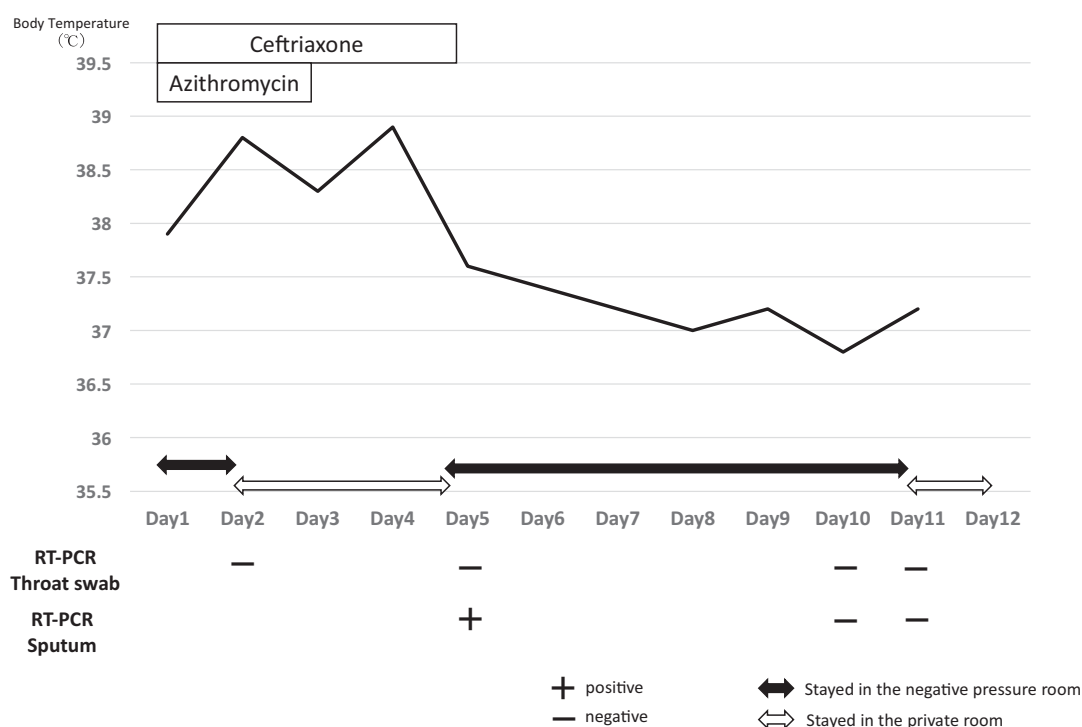


Figure 2. Clinical course.

for diagnosing MERS in the early stages [7]. In our case, the first PCR test was performed on a throat swab because she had no respiratory symptoms and could not produce sputum. However, PCR on sputum obtained on day 5 was positive but a second throat swab obtained on the same day was still negative, suggesting that lower respiratory specimens have higher sensitivity.

Induced sputum should be collected with appropriate precautions. The CDC guideline states that induction of sputum is not indicated [2], and the WHO guideline recommends that sputum induction should be avoided due to high risk of aerosol transmission [8]. In our case, full precautions against airborne transmission were implemented during the sputum collection in the isolation room with negative pressure. In our experience, a nebulizer with hypertonic saline is useful to obtain sputum of good quality.

Our case suggests that COVID-19 cannot be ruled out even when there are no respiratory symptoms in patients with significant travel or exposure history. The patient had only diarrhoea and no respiratory symptoms, although CT scan showed signs of pneumonia. The proportion of patients with respiratory symptoms was reported to be 59.4 and 82% in recent reports on COVID-19 [9,10]. The threshold for performing CT scan should be low to detect slight pneumonia in patients with high clinical suspicion due to travel or exposure history.

In conclusion, we encountered a patient with COVID-19 confirmed by PCR on a lower respiratory specimen but not on throat swabs. Negative PCR test on upper respiratory specimens may not be enough to rule out COVID-19 and a lower respiratory specimen should be collected with appropriate precautions when clinical suspicion is high.

Acknowledgements

Written informed consent was obtained from the patient.

Disclosure statement

The authors report no conflict of interest.

References

- [1] World Health Organization. Novel coronavirus (2019-nCoV), Situation Report-37. [cited 2020 Mar 19]. Available from: https://www.who.int/docs/default-source/coronaviruse/situation-reports/20200226-sitrep-37-covid-19.pdf?sfvrsn=6126c0a4_4.
- [2] Centers for Disease Control and Prevention. Interim guidelines for collecting, handling, and testing clinical specimens from persons under investigation (PUIs) for 2019 novel coronavirus (2019-nCoV). [cited 2020 Mar 19]. Available from: <https://www.cdc.gov/coronavirus/2019-nCoV/lab/guidelines-clinical-specimens.html>.

- [3] Shirato K, Nao N, Katano H, et al. Development of genetic diagnostic methods for novel coronavirus 2019 (nCoV-2019) in Japan. *Jpn J Infect Dis.* 2020. DOI:10.7883/yoken.JJID.2020.061
- [4] Tang P, Louie M, Richardson SE, Ontario Laboratory Working Group for the Rapid Diagnosis of Emerging Infections, et al. Interpretation of diagnostic laboratory tests for severe acute respiratory syndrome: the Toronto experience. *CMAJ.* 2004;170(1):47–54.
- [5] Memish ZA, Al-Tawfiq JA, Makhdoom HQ, et al. Respiratory tract samples, viral load, and genome fraction yield in patients with Middle East respiratory syndrome. *J Infect Dis.* 2014;210(10):1590–1594.
- [6] Centers for Disease Control and Prevention. Interim guidelines for collecting, handling, and testing clinical specimens from persons under investigation (PUIs) for Middle East Respiratory Syndrome Coronavirus (MERS-CoV) – Version 2.1. [cited 2020 Mar 19]. Available from: <https://www.cdc.gov/coronavirus/mers/guidelines-clinical-specimens.html>.
- [7] Huh HJ, Ko JH, Kim YE, et al. Importance of specimen type and quality in diagnosing Middle East Respiratory Syndrome. *Ann Lab Med.* 2017;37(1):81–83.
- [8] World Health Organization. Interim guidance. Clinical management of severe acute respiratory infection when novel coronavirus (2019-nCoV) infection is suspected. [cited 2020 Jan 28]. Available from: <https://www.who.int/docs/default-source/coronaviruse/clinical-management-of-novel-cov.pdf>.
- [9] Wang D, Hu B, Hu C, et al. Clinical characteristics of 138 hospitalized patients with 2019 novel coronavirus–infected pneumonia in Wuhan, China. *JAMA.* 2020;323(11):1061–1069.
- [10] Chen N, Zhou M, Dong X, et al. Epidemiological and clinical characteristics of 99 cases of 2019 novel coronavirus pneumonia in Wuhan, China: a descriptive study. *Lancet.* 2020; 395(10223):507–513.